



PATIENT

Nelly Eotel

SPECIES

Canine

BREED

Whippet

SEX

FS

AGE

3 years

WEIGHT

INTERPRETED BY

Remo Lobetti, BVSc,
MMedVet (Med), PhD,
Dipl. ECVIM

IMAGING PERFORMED BY

Brent Crutchfield, DVM

HOSPITAL NAME

Treasure Coast Animal
Emergency

REFERRING VET

Dr Cail

INVOICE

303439

DATE

9/29/22

PRESENTING CLINICAL SIGNS

History: Diarrhea past week, recent hematemesis.

Physical Examination: N/A.

Urinalysis: N/A

CBC: N/A.

Serum Biochemistry: N/A.

Radiographic Findings: N/A.

ULTRASONOGRAPHIC EXAMINATION OF THE ABDOMEN

Urinary System

Small urinary bladder with a normal thickness (0.3 cm) and appearance of the wall. Normal anechoic urine with no sediment or uroliths evident.

Normal trigone area, proximal urethra, and iliac blood vessels.

Normal iliac lymph nodes. Ureters not visualized.

Normal renal size (left 5.4 cm, right 5.8 cm), echogenic appearance, cortico-medullary differentiation, pelvis and capsule.

Reproductive System

N/A.

Adrenal Glands

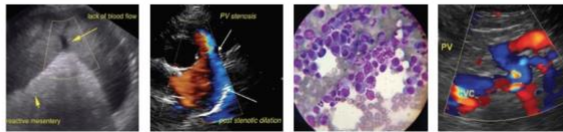
Normal shape, echogenic appearance, position, and size. Left 0.53 cm, right 0.55 cm.

Spleen

Normal size and echogenic appearance. Smooth homogenous parenchyma, regular curvilinear capsule, and normal vasculature. No evidence of inflammatory, neoplastic, infarction, or infiltrative changes noted.

Liver

Normal size, echogenic appearance, portal markings, and curvilinear capsule. Small hypoechoic parenchymal nodule (0.7 x 1.1 cm) in the caudal left lobe. No masses evident. Small gall bladder containing normal anechoic bile. Normal thickness (0.1 cm) and echogenic appearance of the gall bladder wall. Normal bile duct.



PATIENT

Nelly Eotel

SPECIES

Canine

BREED

Whippet

SEX

FS

AGE

3 years

WEIGHT

INTERPRETED BY

Remo Lobetti, BVSc,
MMedVet (Med), PhD,
Dipl. ECVIM

IMAGING PERFORMED BY

Brent Crutchfield, DVM

HOSPITAL NAME

Treasure Coast Animal
Emergency

REFERRING VET

Dr Cail

INVOICE

303439

DATE

9/29/22

Gastrointestinal

Normal appearance of the gastro-esophageal and ileo-cecal junction. Mild segmental thickening of the stomach (0.39 cm), duodenum (0.46 cm), small intestine (0.35 cm) and colon (0.31 cm) with no loss of layering or distension of the lumen. Sections of the small intestine have a corrugated appearance. Gas within the stomach. Large amount of fluid/fecal material within the colon.

Pancreas

Normal size and echogenic appearance. Regular capsule. Normal echogenic appearance of the mesentery and fat surrounding the pancreas.

Free Abdomen

Normal mesenteric lymph nodes (2.7 cm).
Moderate amount of cellular ascites.

ULTRASONOGRAPHIC FINDINGS

Primary findings:

- Gastro-enteropathy.
- Hepatic nodule.

Secondary findings:

- None.

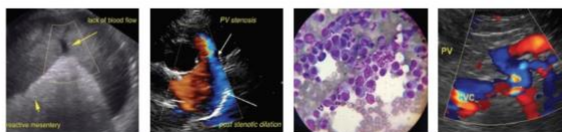
INTERPRETATION OF THE FINDINGS & FURTHER RECOMMENDATIONS IMAGES

Etiologies for the gastro-enteropathy would be non-specific (viral, bacterial, protozoal helminths, dietary indiscretion, toxins), inflammatory bowel disease, and dietary hypersensitivity.

The hepatic nodule is most likely an area of nodular hyperplasia but needs to be monitored and aspirated if enlarges.

Further assessment would be fecal analysis.

Management would be fluid therapy as needed, intestinal diet, anti-emetics, and intestinal protectants/absorbents.



PATIENT

Nelly Eotel

SPECIES

Canine

BREED

Whippet

SEX

FS

AGE

3 years

WEIGHT

INTERPRETED BY

Remo Lobetti, BVSc,
 MMedVet (Med), PhD,
 Dipl. ECVIM

IMAGING PERFORMED BY

Brent Crutchfield, DVM

HOSPITAL NAME

Treasure Coast Animal
 Emergency

REFERRING VET

Dr Cail

INVOICE

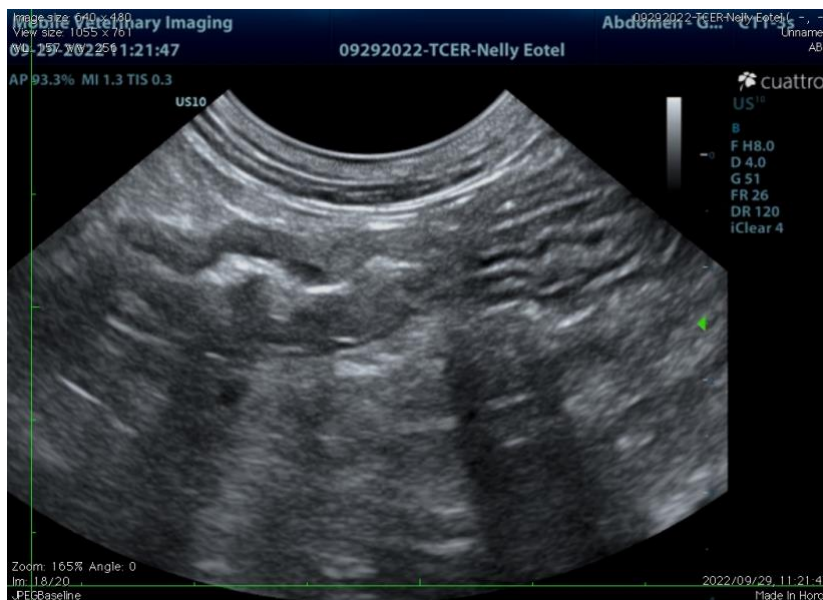303439

DATE

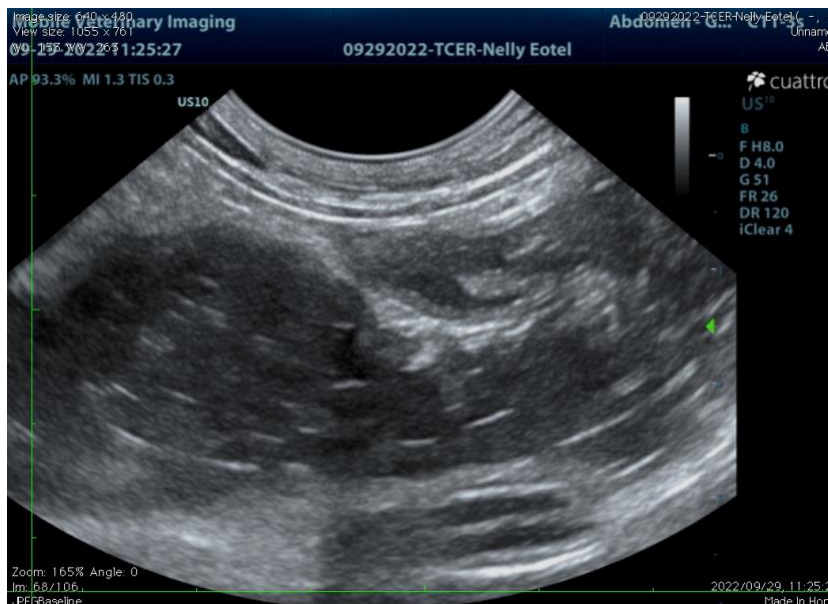9/29/22

IMAGES

Small intestine



Colon





PATIENT

Liver

Nelly Eotel

SPECIES

Canine

BREED

Whippet

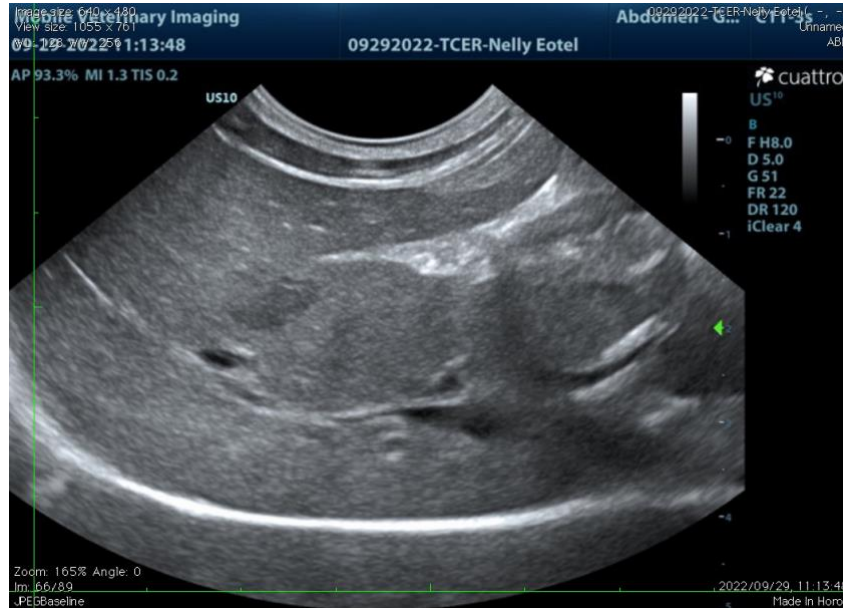SEX

FS

AGE

3 years

WEIGHT



INTERPRETED BY

Remo Lobetti, BVSc,
MMedVet (Med), PhD,
Dipl. ECVIM

The information and recommendations provided are based on the images presented by the referring veterinarian. No evaluation can be communicated regarding pathology that was not visible in the image/video clips provided.

Thank you for this referral. If the clinical or image interpretation does not parallel your findings or if I can be of any further assistance please contact me.

Remo Lobetti, BVSc, MMedVet (Med), PhD, Dipl. ECVIM (Internal Medicine)
rlobetti@mweb.co.za

IMAGING PERFORMED BY

Brent Crutchfield, DVM

HOSPITAL NAME

Treasure Coast Animal
Emergency

REFERRING VET

Dr Cail

INVOICE

303439

DATE

9/29/22